

Radiological Assessment of Epiphora by Dacryocystography

Hara M.¹, Parashar H.²

¹Dr. Mamta Hara, Junior Specialist, ²Dr. Hemendra Parashar, Medical Officer; both authors are affiliated with SRG Hospital & Medical College Jhalawarrajasthan.

Address for Correspondence: Email id: ashwani.rathade@gmail.com

Abstract

Objectives- To find out various causes of epiphora, level and type of block in lacrimal passage, lacrimal pump function, causes of failed dacryocystorhinostomy. **Materials and Methods-** Dacryocystography was done in 100 eyes of 83 patients of epiphora and divided in three groups, Epiphora with patent lacrimal system, non patent lacrimal system, and residual epiphora after the operation of dacryocystorhinostomy. Dacryocystography was performed by using 0.5-1 ml of urografin 76% with the lacrimal cannula and X-ray during forceful injection of the dye. A-P lateral & PNS waters view (magnified) were taken by 500 na X-ray Machine. **Results-** Incidence of epiphora was 41% Right eye, 39% Left eye, 20% both eyes. Male female ratio, 16:84. All age groups are affected almost equally with slight higher incidence in 6th decade in female. On the basis of dacryocystography, Complete block in 60% cases, partial block in 9% cases, and no block was observed in 31% cases. Level of block was at Canalicular in 3%, at common canalicular in 7%, at lacrimal sac-duct junction in 84% and at lower end of nasolacrimal duct in 6% of cases. Prevalence of associated ENT disorders about in 24% and atonic sac in 4 cases. **Conclusions-** Dacryocystography is a simple, easy, cheap, safe and less time consuming investigation, which can be done even at most peripheral level of health services where X-ray facilities are available.

Keywords: Atonic sac, Dacryocystography, Dacryocystorhinostomy, Epiphora, Urografin

Introduction

Epiphora or excessive drainage of water from the eye is almost a universal symptom of disease of lacrimal passage resulting due to improper drainage of tears. It is a very common condition in our rural setup due to unhygienic living conditions illiteracy, poverty, and ignorance and poor infrastructure of health services.

Epiphora due to the lacrimal puncta are misplaced or absent, the lacrimal passage is blocked by atresia, trauma, foreign body or neoplasm. The nose may be obstructed by nasal polyp extreme deviation of nasal septum or inferior turbinate hypertrophy. The Lacrimal pump failure. Adequate assessment of epiphora is necessary for diagnosis & management by syringing & probing of lacrimal passage and dacryocystography

Aims and Objectives

This prospective study has been done with the idea of evaluating & establishing the usefulness of dacryocystography in patients with epiphora for an

ophthalmologist to properly plan out the management. To find out various causes of epiphora, level and type of block in lacrimal passage, lacrimal pump function, causes of failed dacryocystorhinostomy.

Material & Method

The present study was conducted in Department of Ophthalmology in found collaboration of Department of Radiodiagnosis, SRG Hospital & Medical College Jhalawar During 2016 to 2017. 100 eyes of 83 patients complaining of epiphora were selected for dacryocystography and divided in the following groups

- 1- Epiphora with patent lacrimal system
- 2- Epiphora with non patent lacrimal system
- 3- Case of residual epiphora after the operation of dacryocystorhinostomy.

Patients with acute or sub acute inflammation were excluded. The 24 G cannula is introduced in punctum. A 30 cm long catheter attached with a 10 cc syringe, is connected to the lacrimal cannula with 0.5-1 ml of urografin 76% is injected. X-ray exposures are made during forceful injection of the dye. A-P lateral & PNS

Manuscript received: 4th May 2017
Reviewed: 14th May 2017
Author Corrected: 20th May 2017
Accepted for Publication: 24th May 2017

Original Research Article

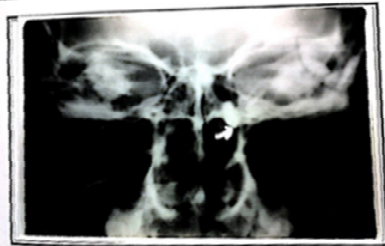waters view (magnified) were taken by 500 na X-ray Machine. On basis of Radiological criteria of abnormal Dacryocystography Level of Block

- 1- Canalicular block
- 2- Common Canalicular block
- 3- Block at sac-duct junction
- 4- Blocks at lower end of nasolacrimal duct
- 5- No apparent abnormality

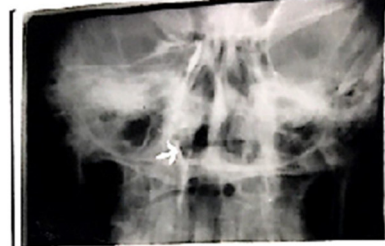On the basis of dacryocystography findings 46 cases were subjected to dacryocystorhinostomy operation.

For clinical correlation of findings of dacryocystography, methylene blue dye was injected in lacrimal passage on operation table & findings were correlated by direct visualization.

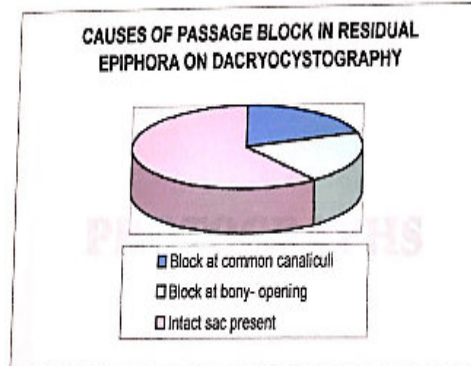
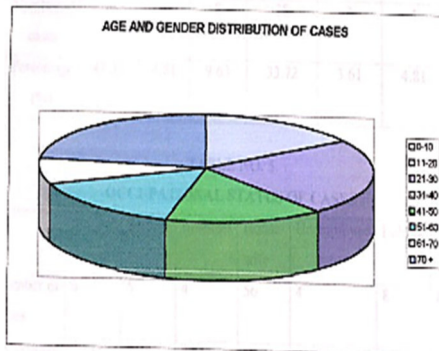
Observation



Photograph No. : 10
Dacryocystogram (A-P view) depicting complete block at lacrimal sac and nasolacrimal duct junction.



Photograph No. : 5
Dacryocystogram (A-P view) depicting normal lacrimal passage with spillage of dye in nasal cavity around a soft tissue mass.



Prevalence of Associated ENT Diseases

ENT disease	No. of cases	Percentage (%)
DEVIATED Nasal Septum	3	3.61
Inferior Turbinate Hypertrophy	4	4.81
Deviated Nasal Septum with Inferior Turbinate Hypertrophy	3	3.61
Chronic Rhinitis	2	2.42
Rhinoporioidosis	1	1.21
Congestion of nasal mucosa	2	2.42
Sinusitis	3	3.61
Atrophic Rhinitis	1	1.21
Suppurative Otitis Media with myringitis	1	1.21
AND	63	75.92
Total	83	100

Level of block

Canalicular Block	1	2.91%
Common Canalicular block	5	7.22%
Sac duct junction block	58	84.05%
Block in nasolacrimal duct	2	2.91%
Block of bony-opening	2	2.91%
Total	69	100%

Discussion

The lacrimal fluid flows over the preocular surface & reaches the marginal tear strip running along the margin of each eyelid & collects as lacuslacrimalis near inner canthus. From the lacuslacrimalis& along the marginal tear strip the lacrimal fluid is then drained by the lacrimal passage through the punctum by capillary action.

Then by the active lacrimal pump mechanism constituted by fibers of the preseptal portion of the orbicularis. The lacrimal pump pushes the fluid into the nasolacrimal duct with the blinking movements of the eyelids.

Right eye involvements was observed in 41% Left eye involvement in 39% 20% cases had epiphora in both eyes. Male: Female ration was 16:84.

All age groups are affected almost equally with slight higher incidence in 6th decade in female where its 27% & also 3rd decade in Males where its 23% the difference may be due to the fact that only certain specific infection are more common in males, Whereas females in general may suffer from chronic irritation leading to chronic dacryocystitis such as caused by smoke etc. while cooking or doing other household work 5.Poor socio-economic status was observed in 92% of cases.6

Type of Blocks- In this study complete block in the lacrimal passage was observed in 60% cases. Whereas 9% cases had partial block. No block was observed in 31% cases due to some inflammatory changes in lacrimal passage in majority of such cases.

Level of Block- Canalicular block in 3% cases, common canalicular block in 7% cases, block at lacrimal sac-duct junction in 84% and lower end of nasolacrimal duct in 6% of cases.5 We have done

dacryocystography in 13 cases of residual epiphora, out of which we found block in 10 cases Out of these cases we observed sommon canalicular block in 20% cases block of bony passage in 20% cases & intact sac was present in 60 & cases.

This clearly shows that most common cause of residual epiphora was due to making and suturing of false flaps of muscular layer or lamellar sac flap i.e. improper sac flaps. Prevalence of associated ENT disorders about in 24% of cases of epiphora.

These included deviated nasal septum, inferior turbinate hypertrophy, deviated nasal septum with inferior turbinate hypertrophy, chornic rhinitis and sinusits . We observed atonic sac in 4 cases.

Summary and Conclusion

We have found dacryocystography to be a simple, easy, cheap, safe and less time consuming investigation which can be done even at most peripheral level of health services where X-ray facilities are available.

It is most informative in relation to localizing exact level of block and associated pathology as compared to other sophisticated investigations which require modern high technology that happen to be very costly and not easily available in most parts of our country dacryocystography does not lead to any complication or after effects.

Funding: Nil, Conflict of interest: None.
Permission of IRB: Yes

References

1. Ewing A.E/ "Roentgen Ray demonstrations of the lacrimal abscess cavity America Journal of Ophthalmology, 1909:26:1

Original Research Article

2. Agrawal M.L. Dacryocystography in chronic dacryocystitis. American Journal of Ophthalmology 1961: 52:245

3. Bansal R.K. Jain A.L Om Prakash “Dacryocystography in normal lacrimal drainage system “Indian journal of Radiology, 1970:163.

4. Campbell William “The Radiology of lacrimal system “British Journal of Radiology, 1964:37:1

5.Nahata M.C: “Dacryocystography in diseases of lacrimal sac” American Journal of Ophthalmology, 1964:58:490.

.....
How to cite this article?

Hara M, Parashar H. Radiological Assessment of Epiphora by Dacryocystography. Trop J Ophthalmol Otolaryngol.2017;2(1):10-13. doi: 10.17511/jooo.2017.i01.03.

.....